



PRESENTING CLINICAL SIGNS

DATE

12/20/22

History: Presented earlier this month with congestion and mucoid nasal discharge. History of allergies and is FeLV positive. Steroid injection two weeks ago did not help. Now increasingly dyspneic, not eating, and likely not drinking. Started furosemide yesterday. CXR on 12/16/22 unremarkable.

ECHOCARDIOGRAPHIC FINDINGS

PERFORMED BY:

2D, M-mode, and Doppler study.

Rachel Runnells, RVT

INTERPRETED BY

Keith Blass, DVM,
MS, DACVIM
(Cardiology)

Left atrial size is normal. The mitral valve is normal. Left ventricular wall thickness is normal. Left ventricular internal dimensions are normal. Left ventricular systolic function is hyperdynamic. The aorta and aortic valve are normal. There is mild right atrial dilation. Right ventricular dimensions are normal. The tricuspid valve appears normal, though mild tricuspid regurgitation is present. TR velocity does not suggest the presence of pulmonary hypertension. The pulmonary artery and pulmonic valve are normal. No shunting lesions are visualized. No pericardial effusion or cardiac masses are seen.

PATIENT

Lio Waring

LA/Ao - 1.25
IVSd - 5.0 mm
LVPWd - 4.7 mm
LVIDd - 12.8 mm
LVIDs - 5.4 mm
FS - 47.8%

SPECIES

Feline

LVOT - 0.88 m/s
RVOT - 1.27 m/s
TR - 1.43 m/s

ASSESSMENT/RECOMMENDATIONS

BREED

DSH

This examination demonstrates mild regurgitation of blood across Lio's tricuspid valve. The hemodynamic effects of the regurgitation also appear to be mild, as Lio does not have secondary dilation of either of his right heart chambers. As such, Lio's current risk for the development of clinical signs secondary to his tricuspid regurgitation appears to be low.

SEX

MN

The absence of left-sided cardiac disease in this exam indicates that Lio's dyspnea does not appear to be cardiogenic in origin.

AGE

8 y

No cardiac therapy is recommended based on this exam.

A recheck echocardiogram is recommended in 9-12 months, sooner if new clinical signs compatible with cardiac dysfunction develop.

WEIGHT

9 lb

HOSPITAL NAME

SVS Imaging KC

REFERRING VET

Dr. Carlson



DATE

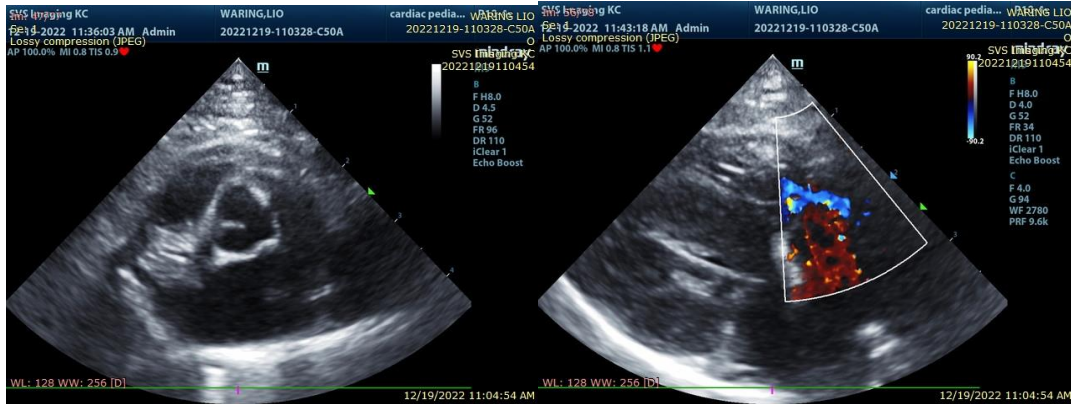
12/20/22

PERFORMED BY:

Rachel Runnells, RVT

INTERPRETED BY

Keith Blass, DVM,
MS, DACVIM
(Cardiology)



The information and recommendations provided are based on the images presented by the referring veterinarian. No evaluation can be communicated regarding pathology that was not visible in the image/video clips provided.

PATIENT

Lio Waring

Thank you for this referral. If the clinical or image interpretation does not parallel your findings or if I can be of any further assistance please contact me.

SPECIES

Feline

Keith Blass, DVM, MS, DACVIM (Cardiology)
KeithBlass@gmail.com
631-804-5754

BREED

DSH

SEX

MN

AGE

8 y

WEIGHT

9 lb

HOSPITAL NAME

SVS Imaging KC

REFERRING VET

Dr. Carlson